Print book

Heart Anatomy

Heart Anatomy

Site:	Hayden-McNeil Online Course
Course:	Indian River State College - BSC2086L -AP II - Summer A 2022
Book:	Heart Anatomy
Printed by:	Oubideh Ramadan
Date:	Monday, May 9, 2022, 11:55 AM

Table of contents

Learning Objectives

Heart Anatomy from Models and Dissected Hearts

Exterior Surface of the Heart

Coronary Vessels

Interior View

Blood Flow through the Heart

Cardiac Muscle

Virtual Heart Dissection

Transverse Sections through the Heart from Apex to Base, Approximately One-Inch Sections

Surface View (All of the lines are structures listed on Anatomical Structures to Identify)

Right Ventricle (opened)

Internal View (left and right sides, coronal section)

Left Side (dissected)

Pulses

Blood Pressure

Orthostatic Blood Pressure

Exercise Experiment

Reference Information for BP

Conduction System

EKG/ECG

Cardiac Conduction with Resultant EKG

EKG Lead Placement

Heart Physiology (Wiggers Diagram)

Pulse, Blood Pressure, and EKG Lab Questions

Post Lab Questions for Wiggers Diagram

Heart Anatomy

Learning Objectives

- Be able to identify the heart structures listed on the following page on the heart model and the dissected pig heart
- Know the function of each anatomical structure
- Be able to **trace the path of a drop of blood** through the heart from the systemic circulation to and from the pulmonary circulation and back to the heart, naming chambers, valves, and vessels
- Be able to explain the basics of pulse, blood pressure, EKG, and how they all relate to heart function and structure

Heart Anatomy from Models and Dissected Hearts

ANATOMICAL STRUCTURES TO IDENTIFY

Pulmonary Vessels

Layers of Heart

- Parietal pericardium
- Visceral pericardium (epicardium)
- Myocardium
- Endocardium

Heart Chambers

- Auricles
  - Right auricle
  - Left auricle
- Atrium
  - Right atrium
  - Left atrium
- Ventricles
  - Right ventricle
  - Left ventricle

External Vessels on or near the Heart

Coronary Arteries

- Right coronary artery
- Left coronary artery
- Left anterior descending coronary artery
- Circumflex coronary artery
- **Coronary sinus** (main vein that drains the coronary arteries into the right atrium)

Aorta Sections

- Ascending aorta
- Aortic arch
- Descending thoracic aorta

Branches of the Aortic Arch

- Brachiocephalic trunk
- Left common carotid artery
- Left subclavian artery

- Pulmonary trunk (pulmonary artery)
- Pulmonary arteries
  - Left pulmonary artery
  - Right pulmonary artery
- Pulmonary veins
  - Left pulmonary vein
  - Right pulmonary vein

Other Vessels

- Vena Cava
  - Superior Vena Cava (SVC)
  - Inferior Vena Cava (IVC)

Heart Valves

- Atrioventricular valves (AV valves)
  - Tricuspid valve (Right AV valve)
  - Bicuspid (mitral) valve (Left AV valve)
- Semilunar valves
  - Aortic semilunar valve
  - Pulmonic semilunar valve

Heart Structures

- Interventricular septum
- Anterior interventricular sulcus
- Coronary sinus opening into the right atrium
- Fossa ovalis
- Chordae tendineae
- Papillary muscles
- Moderator band

14

HEART ANATOMY

ONLINE

Exterior Surface of the Heart

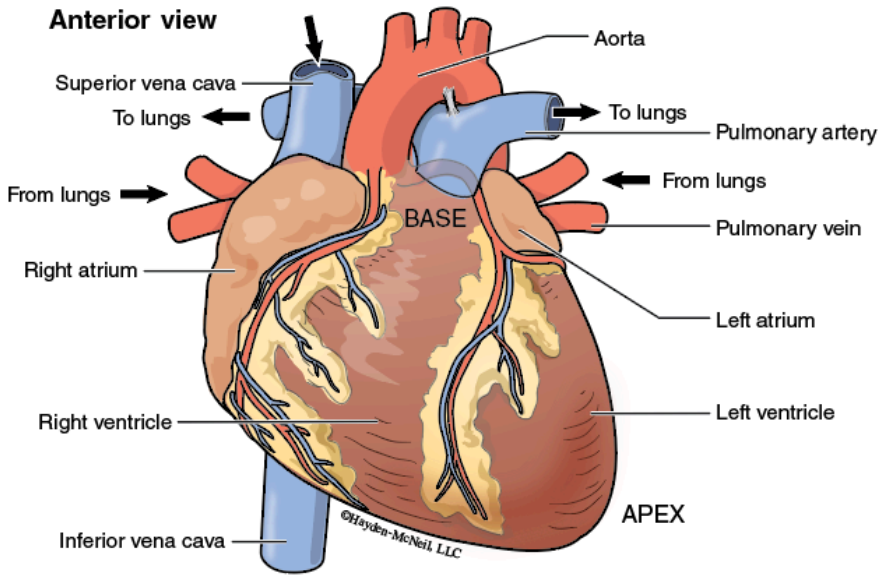

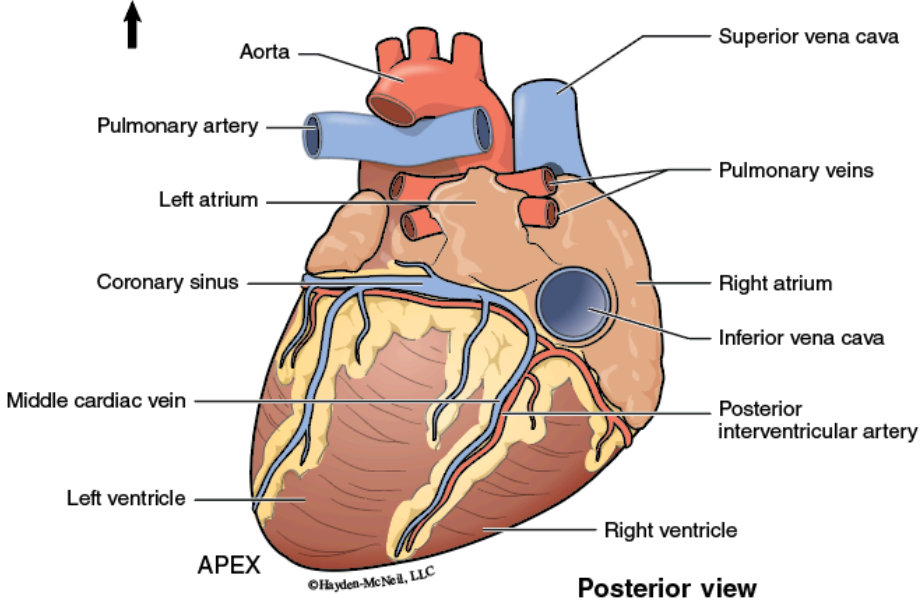

Coronary Vessels

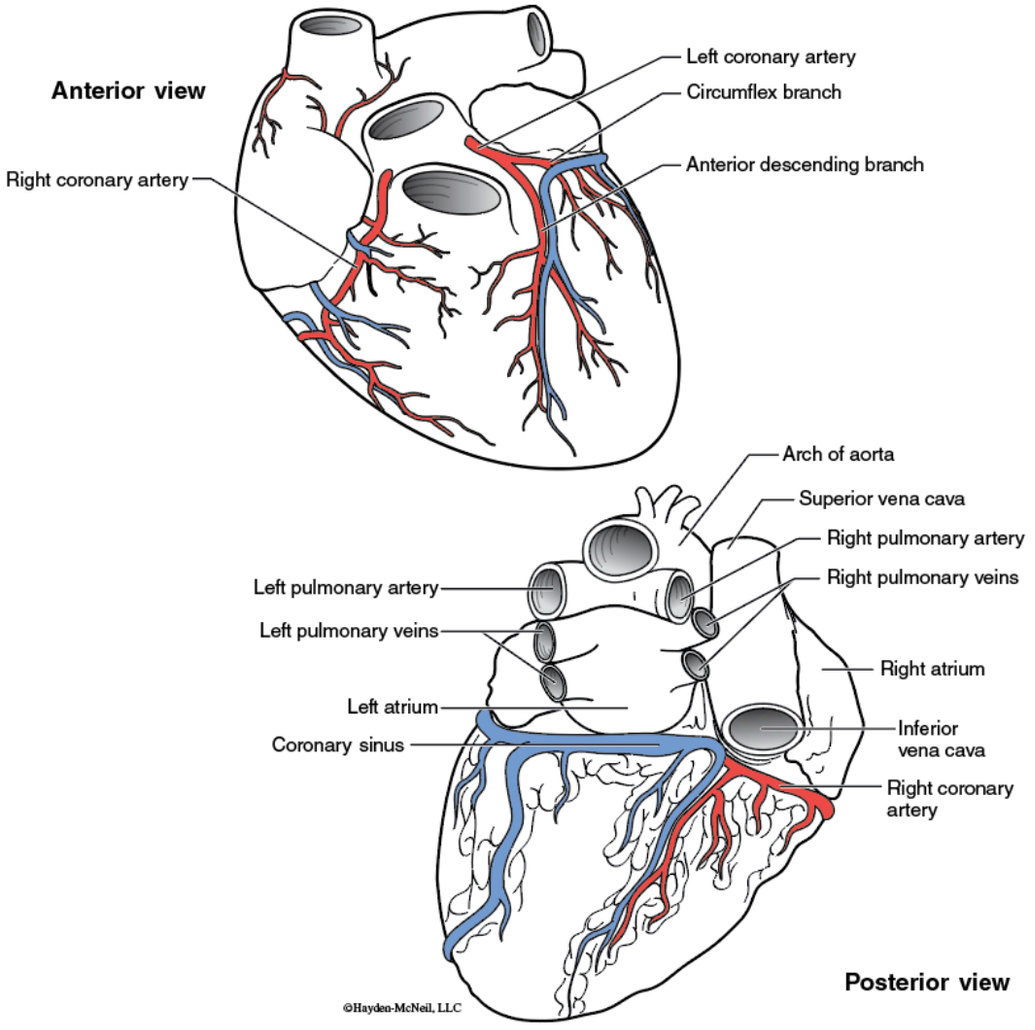

Explanation: Remember back to the skin, as the stratified squamous layers move further and further away from the basial layer, near the blood vessels the cells die without proper blood flow, nutrients and oxygen. Any tissue in the body more than a few cell layers thick **MUST** have its own separate blood flow! For the heart, the myocardium (heart muscle) is extremely thick, so the vessels that function to bring blood flow, oxygen and nutrients to the myocardium are the **CORONARY ARTERIES!** If the coronary arteries become blocked or flow is disrupted for any reason the cells of the myocardium start to die, this is a heart attack or myocardial infarction!

Interior View

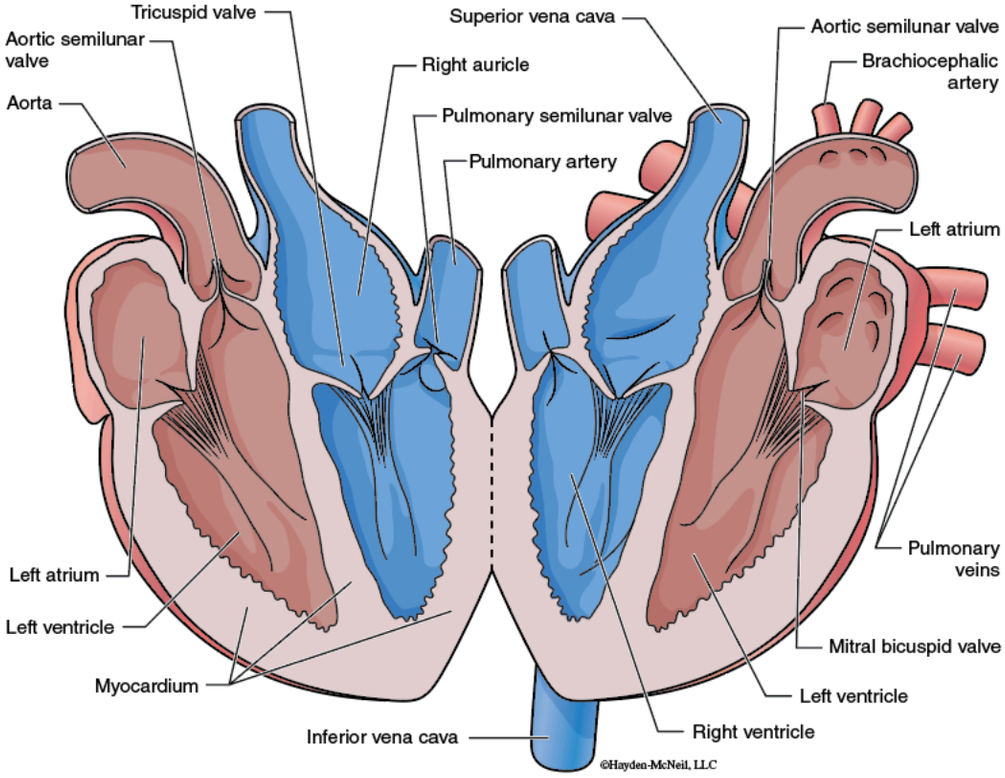

ONLINE

Blood Flow through the Heart

- Flowing into the right atrium
- Left atrium through left atrial

- Superior and inferior venae cavae
- Coronary sinus (from coronary circulation)

- Flows through right atrial ventricular valve (tricuspid)
- Into the right ventricle
- Out the pulmonary semilunar valve through the pulmonary arteries to lungs
- Back to heart through the pulmonary veins to the left atrium
- ventricular valve (BICUSPID OR MITRAL)
- Into the left ventricle
- Out the aortic semilunar valve into the aorta
- To the body through the aortic branches
- Blood back flowing in aorta toward heart enters coronary circulation

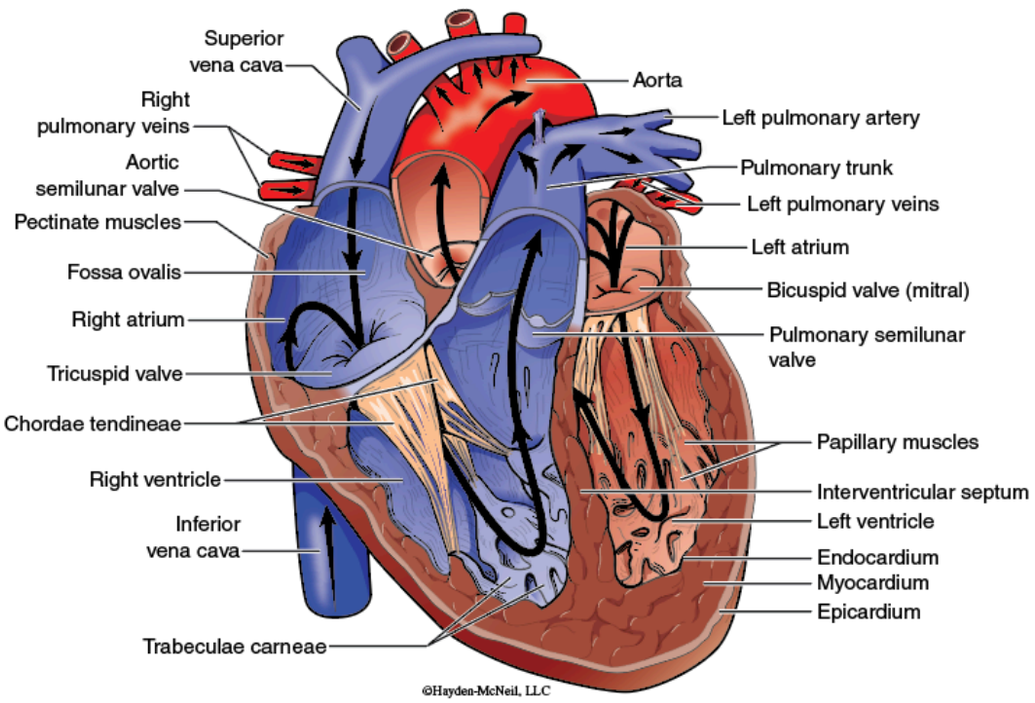

Cardiac Muscle

PHYSICAL CHARACTERISTICS

- Found only in the heart
- Striations
- Nonvoluntary
- Intercalated disks, conduction
- Conduction system (specialized cardiac myocytes for conduction)



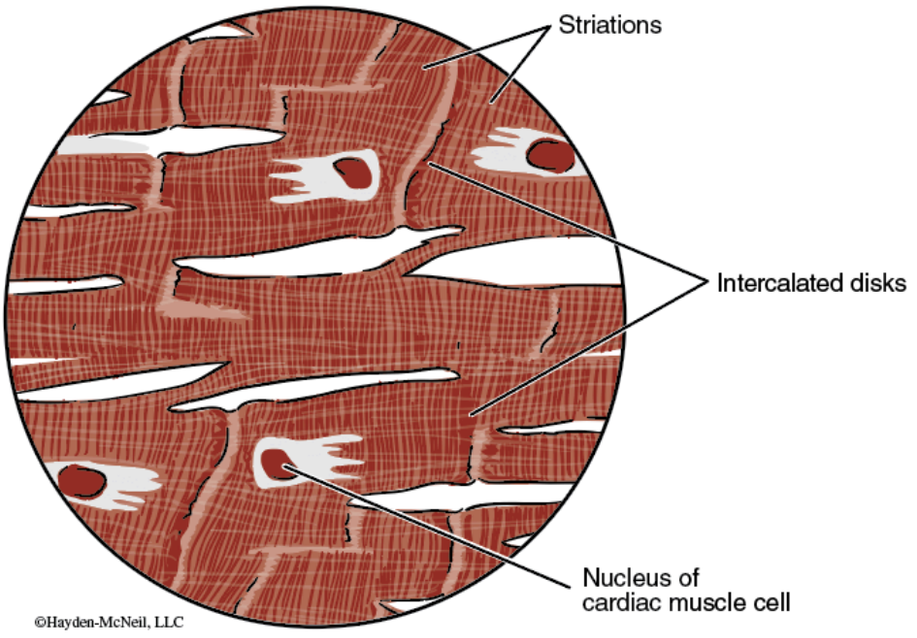

Virtual Heart Dissection

For this section we will be using the 3D4 Medical app to perform a virtual dissection of the heart.

Look up all heart structures using your 3D4 Medical app!

Structures are listed at the start of the Heart Anatomy section labeled "Heart Anatomy from Models and Dissected Hearts: Anatomical Structures to Identify."

- Make sure that you can identify them from various viewpoints
- Add in some structures around the identified structure to help identify what specifically you are looking at.

- Example: If you are labeling the right atrium, you might label the superior vena cava above it and the inferior vena cava below it to show reference points.

Transverse Sections through the Heart from Apex to Base, Approximately One-Inch Sections

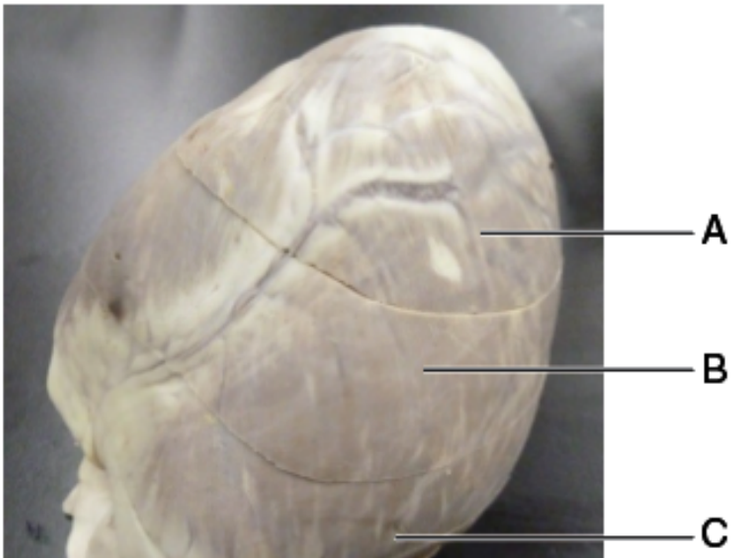

- Pay attention to the size of the left ventricle compared to the right ventricle.
- The majority of the heart is left ventricle based on size.
  - Why is the left ventricle so much larger than the right?
- Many books make the left and right ventricles look similar side by side. From the pictures below, you can see that most of the heart



is left ventricle and the right is actually a flap of muscle that wraps around the right side of the left ventricle, making a chamber. The right wall of the left ventricle is the inner wall of the right ventricle. They are not equal chambers side by side!

ONLINE

The whole heart above is labeled with letters A–E. These letters are specific to each cross section cut through the heart. Below are those sections laid out. Compare what you see with the whole heart above to what you see below for each cross section.

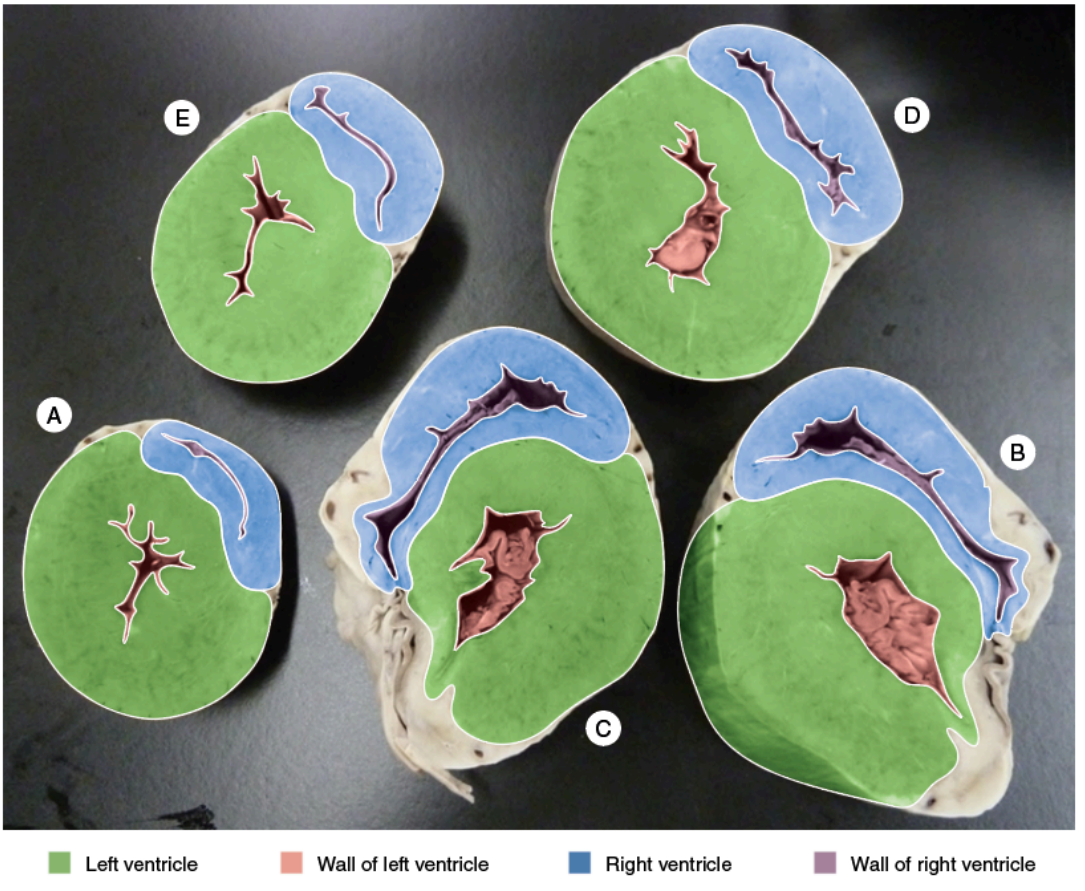

Watch the dissection videos for surface and interior views online.

Surface View (All of the lines are structures listed on Anatomical Structures to Identify)

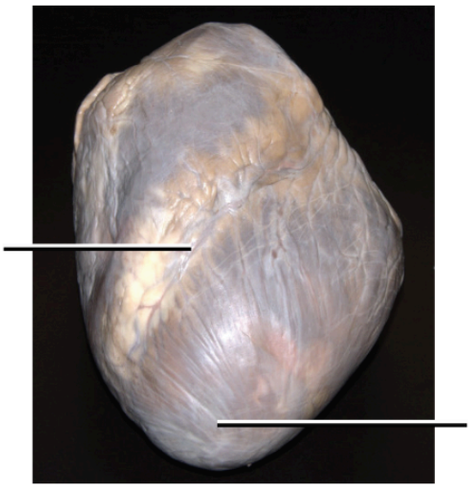

Anterior surface

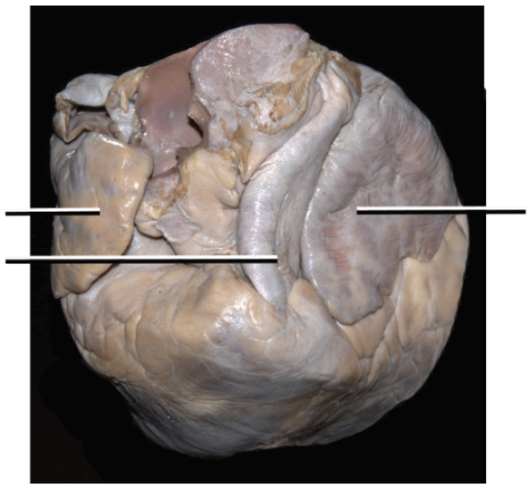

Anterior superior surface

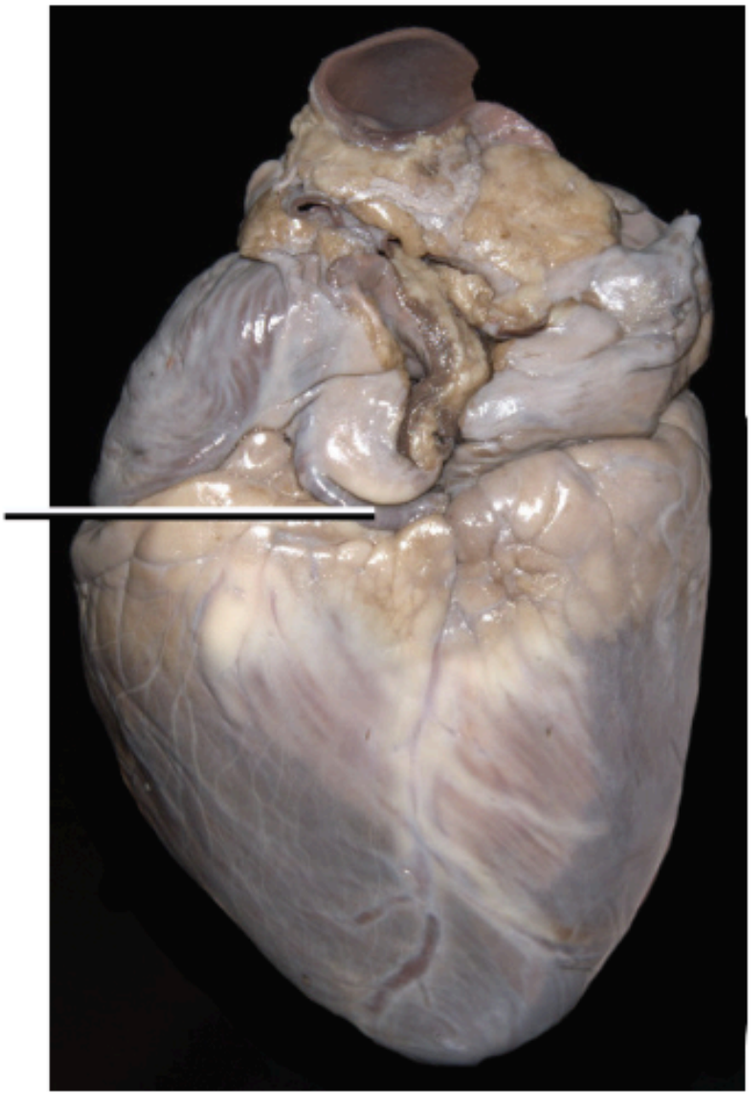

Posterior surface

- Interventricular septum
- APEX of left ventricle
- Left auricle
- Right auricle
- Pulmonary trunk
- Coronary sinus

Right Ventricle (opened)

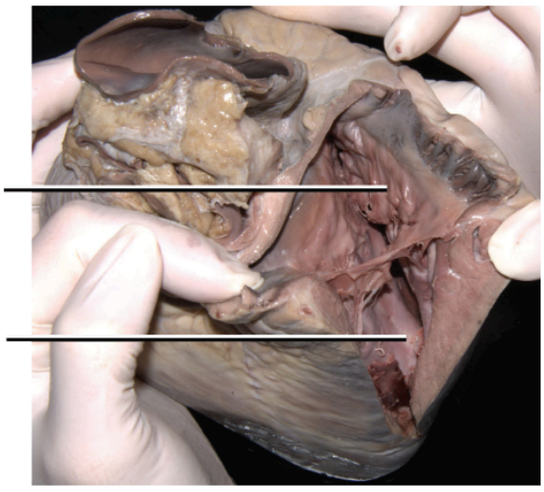

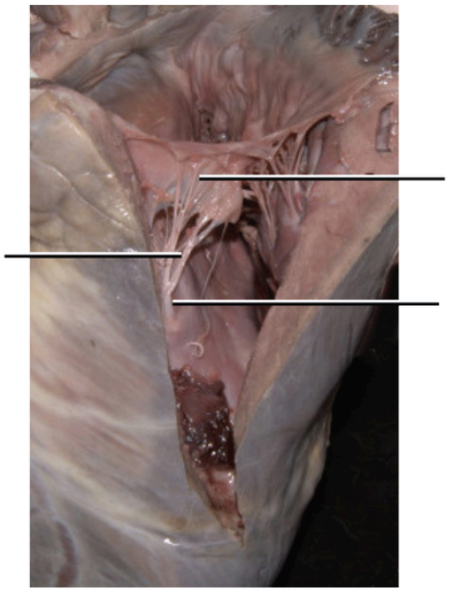

- Moderator band
- Chordae tendineae
- Papillary muscle
- Tricuspid valve
- Right ventricle
- Right atrium

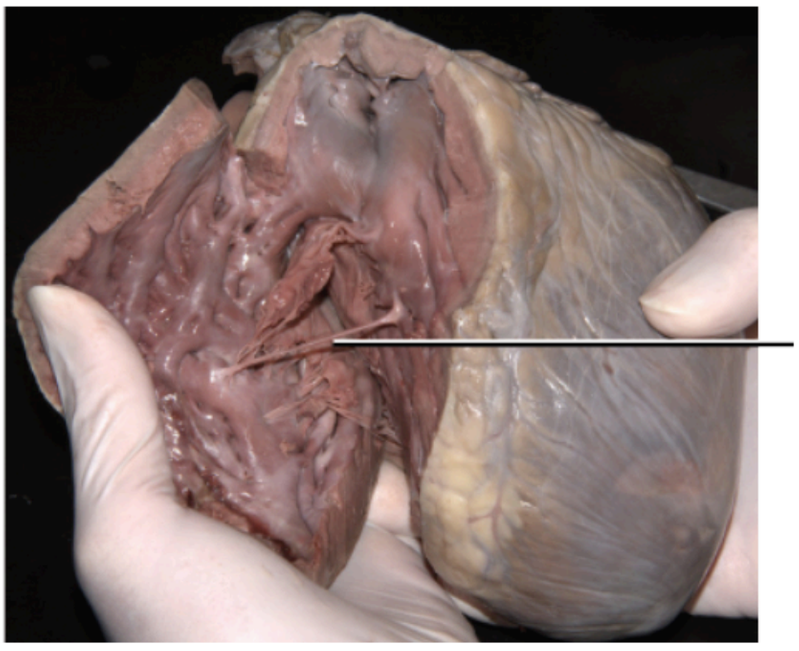

Internal View (left and right sides, coronal section)

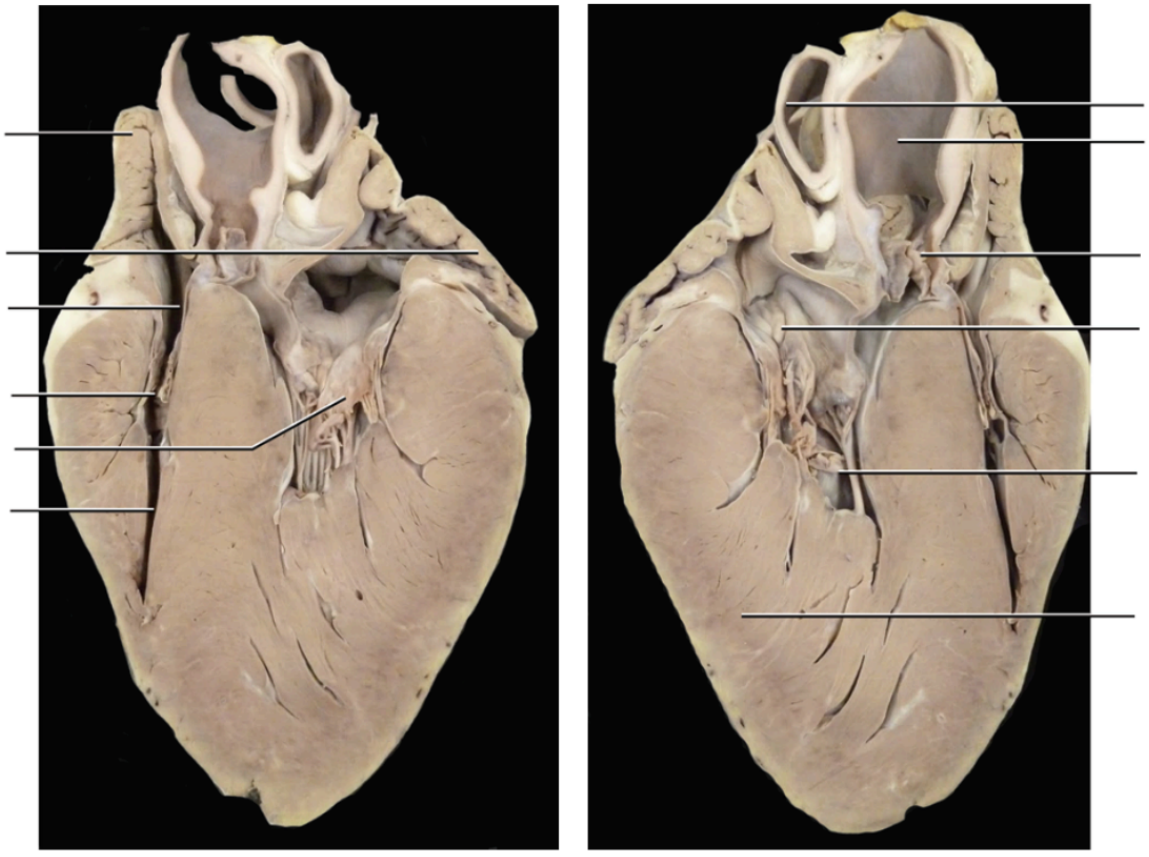

- Left auricle
- Right auricle
- Right atrium
- Left atrium
- Tricuspid
- Bicuspid
- Right ventricle
- Papillary muscle
- Wall of left ventricle
- Aortic semilunar valve
- Aorta
- Pulmonary trunk

ONLINE

Left Side (dissected)

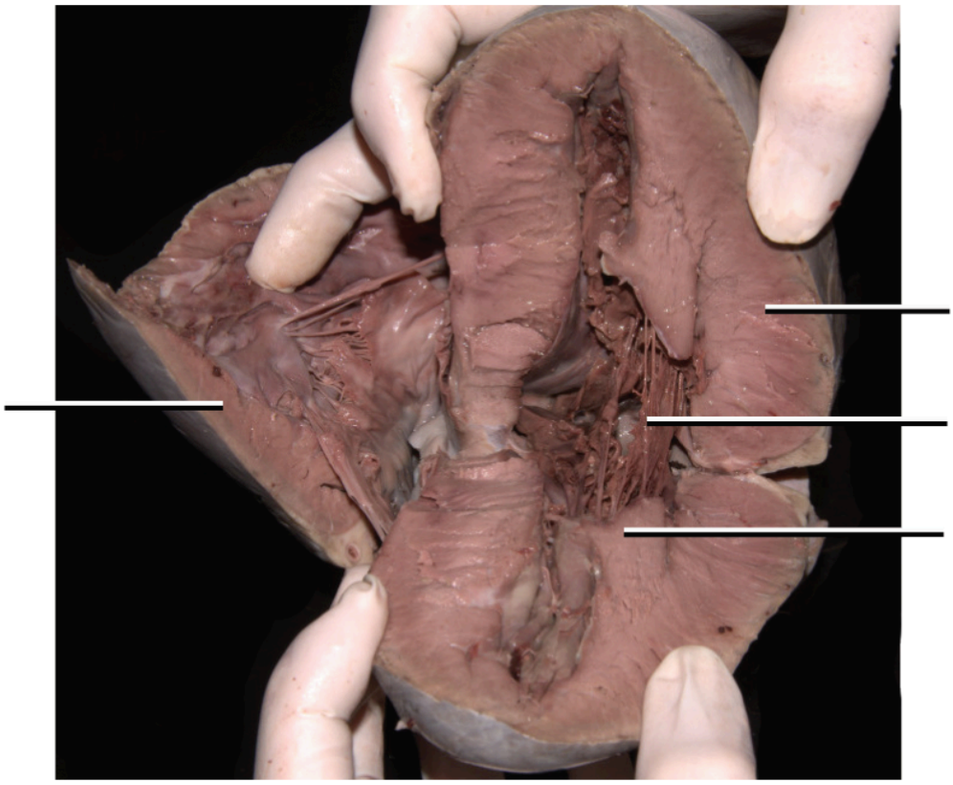

The main view is inferior looking up into the left ventricle (thickness of wall!).
On the side is the wall of the right ventricle.

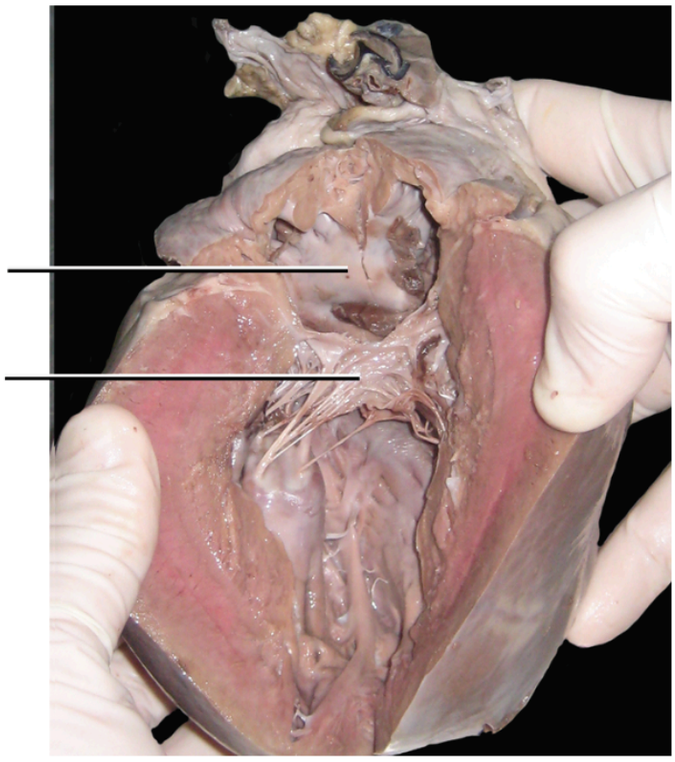

- Wall of right ventricle
- Wall of left ventricle
- Papillary muscle
- Bicuspid valve
- Chordae tendineae
- Left atrium

Side view into the left ventricle and left atrium showing the valve.

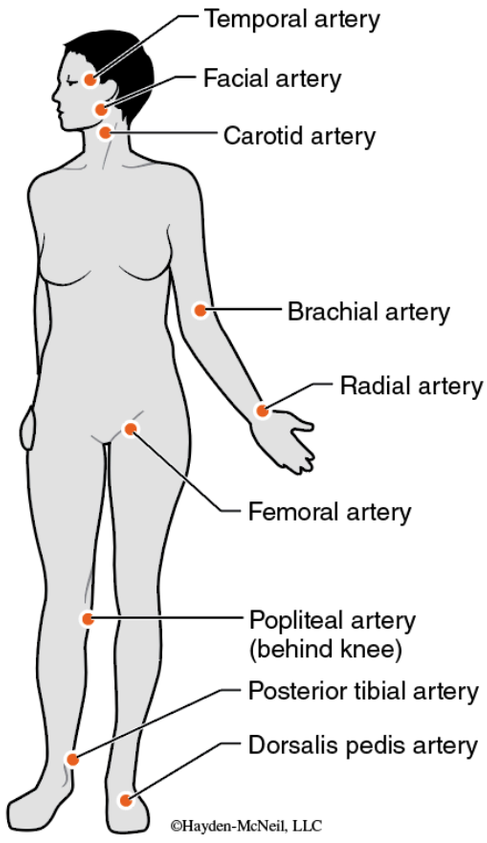

The primary method of measurement: You must know the precise anatomical location of each artery that may be used to measure a pulse. Once you have identified the location of the pulse you will measure, place your finger or fingers (there are various techniques) over the area where you know the artery is. Gently put pressure on the skin over the area (if you press too hard or too deep, you may occlude the blood flow and not feel the pulse).

Relationship to blood pressure: A pulse is the wave of blood pushed through the artery with each beat of the left ventricle. Systolic blood pressure is the force behind the pulse. The higher the systolic blood pressure, the more obvious the pulse usually is. With low blood pressure, if you press too hard on the artery, you can put more pressure on the artery than the heart is creating and subsequently cut off the blood flow, feeling no pulse. Sometimes, if the pressure is really high, you can feel your fingers being pushed off the artery with each pulse!

How long to count: This varies; if all is normal, you can get a good reading counting for 6 seconds and multiplying by 10. If the pulse is irregular, counting for 15 or 30 seconds is going to give you a more accurate reading. Patients who have slow heart rates

need to count for a full minute to get an accurate measure. So again, how long to measure varies; you have to think about the situation and do what is appropriate. Measuring pulses is not a technique with one method that fits all patients!

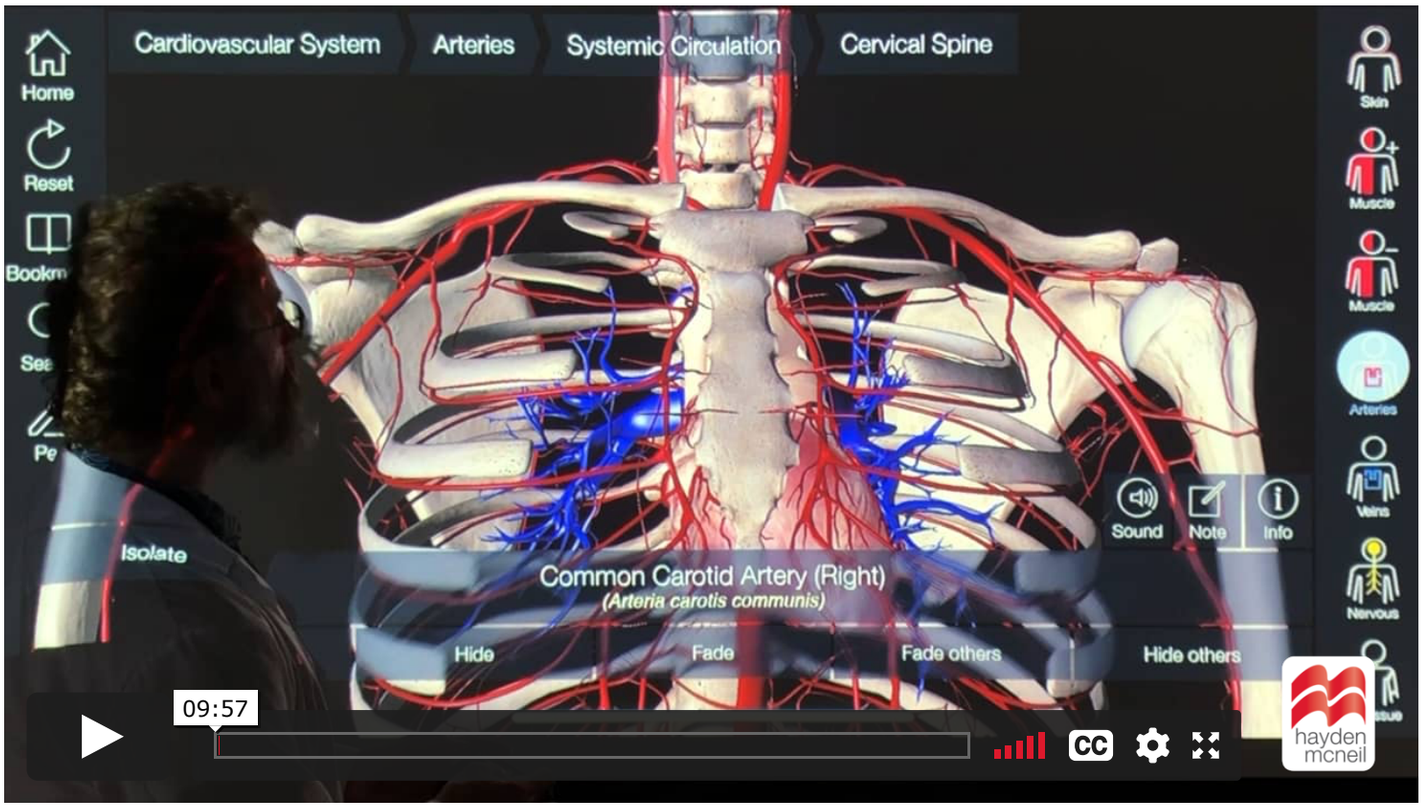

AT HOME EXERCISE

1. Work with your partners to measure their pulse.
2. Measure the pulse in all the locations to familiarize yourself with all the pulse locations.

ONLINE

Artery	Pulse
Carotid	
Brachial	
Radial	
Popliteal	
Posterior tibal/dorsalis pedis	

3. Is the pulse the same in all locations?

4. Does distance from the heart affect the pulse?
5. What is a pulse?
6. Can you detect a pulse without touching the patient?
7. Why can you only feel pulses in specific locations?
8. Do veins pulse?

Blood Pressure

WHAT, HOW, AND WHY

Blood pressure is literally the maximum and minimum pressure in the aorta. When you look at the graph called the Wiggers Diagram, look at the aortic pressure line. The peak of this line is the person's systolic pressure, and the lowest point of the line is their diastolic pressure. When blood is ejected from the left ventricle into the aorta, the pressure the LV created is transmitted to the artery (aorta); this is systolic pressure. Once contraction has occurred and the heart is at rest, this lowest point of pressure is diastolic pressure.

MEASURING BP

For this exercise, you will use a manual cuff with a stethoscope. If you are working from home and have access to a blood pressure cuff, use what you have! If you do not have a stethoscope and blood pressure cuff or an automatic cuff, they can be purchased at the college bookstore, local stores or online.



1. Find the artery that you are going to use for BP. Feel for the pulse at that location and where you will place the stethoscope.
2. Make sure you have the correct size cuff; there are measurement lines on the cuff that tell you if the diameter of the cuff is correct. Outside of these lines, it is either too small or too large; this will give you an incorrect reading.
3. Place the cuff around the arm or leg, wherever you are taking the measurement.
4. There should be a mark or words that indicate the position of the artery. If the artery and those marks are not lined up, you will not get an accurate reading.
5. How high do you pump the cuff? Some instructors teach you to inflate the cuff to 180 to 200 mmHg. This is fine for most of your patients. The reason it is a bad idea is the 10 or 20% of your patients this does not fit: patients with really low pressure and patients with really high pressure. In these patients you are likely going to miss hearing their pressure just pumping up to 180–200 mmHg. These are also the patients that are critical and you need their pressure immediately—you do not have time to attempt it multiple times!
    a. Two methods:
        i. First method:
            A. Feel a pulse distal to the cuff while inflating the cuff. Watch the readings as you increase the pressure. When you no longer feel the pulse, you have cut off blood flow through the artery, and that is about the systolic pressure.

B. Deflate the cuff and repeat the process but with the stethoscope. Pump up the cuff, maybe about 10 to 20 mmHg higher than the pressure where you lost the pulse previously.

C. Let the pressure out of the cuff slowly, but not too slowly. When you reach systolic pressure, you should be able to hear beats through the stethoscope (this is the LV forcing blood through the constricted artery). Watch the numbers as you continue letting out pressure.

D. When you reach the point where the artery is completely open, the sounds will stop. This is the diastolic pressure.

E. You will hear sounds from the systolic reading to the diastolic reading, but not above and below those numbers.

F. Above systolic, the artery is completely constricted—no blood flow, no sound! Below diastolic, the artery is 100% open, and blood flowing through open arteries does not make a sound, normally.

ii. Second method:

A. Pump up the cuff while listening for the sounds through the stethoscope; you skip the part of pumping the cuff up while feeling the pulse.

B. This is quicker, but it takes practice, and if the sounds are hard to hear, you may not get a proper reading or may not hear sounds at all.

C. Practice with the first method, and then move on to this method once you are comfortable with the process.

BLOOD PRESSURE LAB RECORDINGS

First perform the basic procedure to become proficient with taking blood pressure. Do this on multiple people if possible; it is a skill that you can only learn by practicing!

The purpose of this section is to learn what various body positions and/or blood pressure cuff positions can do to the blood pressure measurements.

There are multiple tables to fill out for each individual person. Measure as many as you can!

In the tables below, you have 3 measured variables and 2 calculated variables. The measured variables are heart rate (HR/Pulse), systolic pressure (sys mmHg, largest number of reading) and diastolic (dia mmHg, smallest blood pressure number). The calculated variables are pulse pressure (PP), it is the difference between systolic pressure and diastolic pressure (sys − dia = PP), and mean arterial pressure (MAP) (MAP = dia + 1/3 PP). The term pulse pressure has the word pulse in it but this reading has nothing to do with the pulse/HR!

Measurements (if you are not 100% sure of the measurement, wait a min or two and measure again)

1. Measure blood pressure and pulse in one of the arms at the brachial artery (left or right).
2. Then measure blood pressure in the opposite arm with your patient in the exact same position.
    a. Place these measurements in the table under "left arm" and "right arm."
3. Next pick one of the arms and raise it above their head and measure pressure again.
    a. If your patient has lower blood pressure or long arms, their BP may not be high enough to register far above the head. In this case lower the arm down a bit.
    b. If you have access to a wrist BP cuff, this will give you a greater change, best option!
    c. Record these measurements in the table under "arm up."
4. With the same arm lower their arm down as far as possible, the further below the heart the greater the response will be.
    a. Again, a wrist cuff will give the best results.
    b. Record these measurements in the table under "arm down."
5. Answer post-exercise blood pressure questions.

Record as many people as you need to so you are familiar with taking BP.

Example: HR 70 BPM, systolic pressure 120 mmHg, diastolic pressure 80 mmHg, pulse pressure (120 mmHg – 80 mmHg = 40 mmHg), MAP (80 mmHg + 0.3 (40 mmHg) = 92 mmHg.

HR is the number of beats per minute and is also referred to as the pulse. Normally, HR is something we get from a monitor and pulse is something we feel from the artery.

Systolic is the upper/larger number, maximum arterial pressure

Diastolic is the lower/smaller number, minimum arterial pressure

Pulse pressure is a calculation: Systolic – Diastolic pressure (120 – 80 = 40 mmHg)

ONLINE

Patient	Hr/Pulse (BPM)	Systolic (mmHg)	Diastolic (mmHg)	Pulse Pressure (mmHg)	MAP (mmHg)	Artery Used (Brachial or Radial)	Cuff Type (Manual or Wrist)
Left arm							
Right arm							
Arm up							
Arm down							

Patient	Hr/Pulse (BPM)	Systolic (mmHg)	Diastolic (mmHg)	Pulse Pressure (mmHg)	MAP (mmHg)	Artery Used (Brachial or Radial)	Cuff Type (Manual or Wrist)
Left arm							
Right arm							
Arm up							
Arm down							

Patient	Hr/Pulse (BPM)	Systolic (mmHg)	Diastolic (mmHg)	Pulse Pressure (mmHg)	MAP (mmHg)	Artery Used (Brachial or Radial)	Cuff Type (Manual or Wrist)
Left arm							
Right arm							
Arm up							
Arm down							

QUESTIONS

ONLINE

1. Which systolic reading was highest, above or below the heart?
2. Which systolic reading was lowest, above or below the heart?
3. Which diastolic reading was highest, above or below the heart?

4. Which diastolic reading was lowest, above or below the heart?
5. From the above readings, raising the artery above the heart gives a reading higher or lower than the normal proper position?
6. From the above readings, lowering the artery below the heart gives a reading higher or lower than the normal proper position?
7. Did your readings above and below the heart come close to the calculated change of 2 mmHg/inch above or below the heart?
8. Why did you get the measurement you got above the heart?
9. Why did you get the measurement you got below the heart?
10. In the clinical setting, how would this information affect taking blood pressures?

Orthostatic Blood Pressure

Orthostatic blood pressure measurement is used to test the patient's change in blood pressure from supine to standing. If the patient's cardiovascular system does not respond to change in posture appropriately, they are at risk of passing out. The heart and blood vessels should undergo certain changes to prevent this from occurring; this test tells you if it is responding appropriately and if not, what the issue might be.

METHOD

1. Have the patient lie down in the supine position.
2. Place the cuff on their arm or wrist.
    a. Remember that the artery where BP is being taken must be level with the heart in the plane of gravity. When in the supine position, this is halfway between the anterior and posterior chest, not above the heart. Hand resting at their side, slightly elevated, should be about the correct position.

3. Take a resting BP in the supine position.
    a. Caution: If it is known that they pass out, you may want to have them go from the supine position to a sitting position instead of standing. You do not want to make them pass out or cause an injury. It's safer and easier to deal with low BP or passing out if the patient is sitting!
    b. This is not an actual step of the test, but is used when it is known the patient will pass out.
4. Have them stand up and repeat the test.
5. The test must be performed in this order, supine then standing. The reverse does not tell you anything about the patient's change in BP from supine to standing.

ONLINE

Patient	Hr/Pulse (BPM)	Systolic (mmHg)	Diastolic (mmHg)	Pulse Pressure (mmHg)	Map (mmHg)	Artery Used (Brachial or Radial)	Cuff Type (Manual or Wrist)
Supine							
Sitting							
Standing							

Patient	Hr/Pulse (BPM)	Systolic (mmHg)	Diastolic (mmHg)	Pulse Pressure (mmHg)	Map (mmHg)	Artery Used (Brachial or Radial)	Cuff Type (Manual or Wrist)
Supine							
Sitting							
Standing							

Patient	Hr/Pulse (BPM)	Systolic (mmHg)	Diastolic (mmHg)	Pulse Pressure (mmHg)	Map (mmHg)	Artery Used (Brachial or Radial)	Cuff Type (Manual or Wrist)
Supine							
Sitting							
Standing							

QUESTIONS

ONLINE

1. What did HR do supine to standing?
2. What did systolic pressure do supine to standing?
3. What did diastolic pressure do supine to standing?
4. What did pulse pressure do supine to standing?
5. What caused HR to change, physiological response?
6. What caused systolic pressure to change?
7. What caused diastolic pressure to change?
8. Did pulse pressure change? Should it?

Exercise Experiment

1. Work in your group.
2. Take pulse and BP at rest.
3. Exercise for a minimum of 5 minutes.
4. Take pulse and BP immediately after exercise.
5. Take pulse and BP after 5 minutes of recovery.

ONLINE

Patient	Hr/Pulse (BPM)	Systolic (mmHg)	Diastolic (mmHg)	Pulse Pressure (mmHg)	Map (mmHg)	Artery Used (Brachial or Radial)	Cuff Type (Manual or Wrist)
Pre-exercise							
Immediately Post-exercise							
5-minutes Post-exercise							

Patient	Hr/Pulse (BPM)	Systolic (mmHg)	Diastolic (mmHg)	Pulse Pressure (mmHg)	Map (mmHg)	Artery Used (Brachial or Radial)	Cuff Type (Manual or Wrist)
Pre-exercise							
Immediately Post-exercise							
5-minutes Post-exercise							

Patient	Hr/Pulse (BPM)	Systolic (mmHg)	Diastolic (mmHg)	Pulse Pressure (mmHg)	Map (mmHg)	Artery Used (Brachial or Radial)	Cuff Type (Manual or Wrist)

Pre-exercise							
Immediately Post-exercise							
5-minutes Post-exercise							

QUESTIONS

ONLINE

1. What did HR do during exercise and recovery?
2. What did systolic pressure do during exercise and recovery?
3. What did diastolic pressure do during exercise and recovery?
4. What did pulse pressure do during exercise and recovery?
5. What sensors in the body responded to exercise, such as baroreceptors, chemoreceptors, mechanoreceptors, etc.? Be specific.
6. Briefly explain why each measured variable changed or didn't change.

Reference Information for BP

Classification of Blood Pressure for Adults[1][2]

Category	Systolic, mmHg	Diastolic, mmHg
Hypotension	< 90	< 60
Desired	**90–119**	**60–79**
Prehypertension	120–139	80–89
Stage 1 hypertension	140–159	90–99
Stage 2 hypertension	160–179	100–109
Hypertensive emergency	≥ 180	≥ 110

1. "Understanding blood pressure readings." Heart.org. American Heart Association. 11 January 2011.
2. "Low blood pressure (hypotension)—Causes." MayoClinic.com. Mayo Foundation for Medical Education and Research. 23 May 2009.

Measurement Locations for Taking Blood Pressures (artery being used must be level with the heart):

Artery Being Compressed	Artery Being Auscultated
Brachial	Brachial
Radial	Radial
Femoral	Possibly femoral, usually popliteal

Posterior tibal artery	Posterior tibal artery artery or dorsalis pedis

Readings for BP:

Systolic: Maximum pressure against the artery

Diastolic: Minimum pressure against the artery

Pulse Pressure (PP): Sys − Dia

Mean Arterial Pressure (MAP): Dia + 1/3(PP)

Conduction System

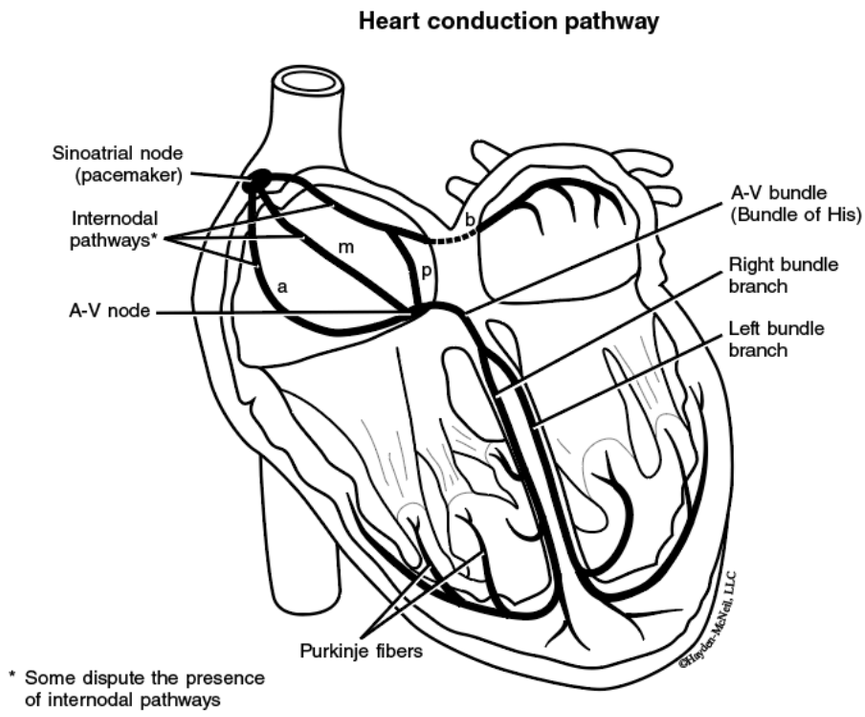

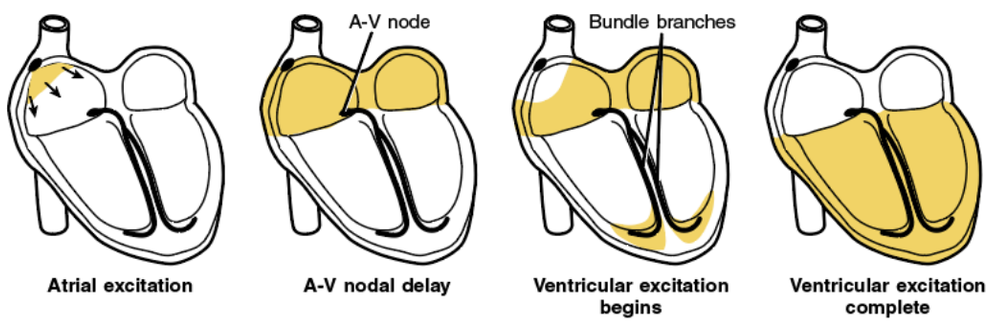

EKG/ECG

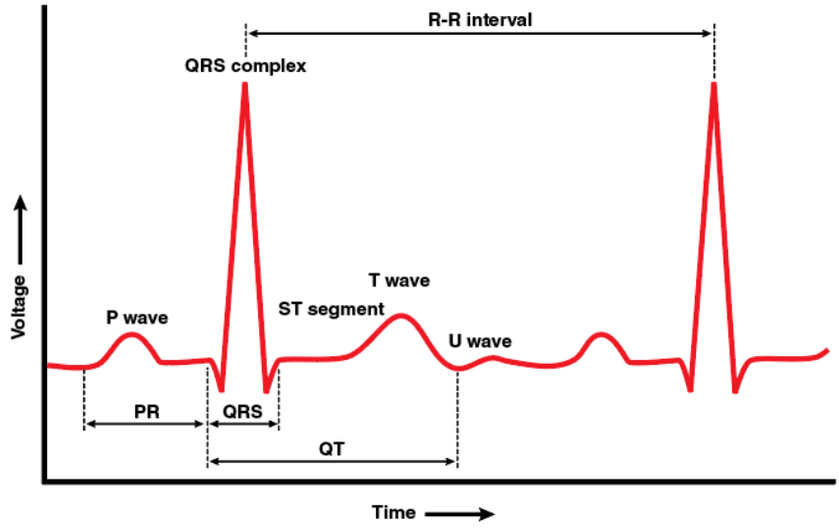

- P wave: the *sequential* activation (depolarization) of the right and left atria
- PR interval: time interval from onset of atrial depolarization (P wave) to onset of ventricular depolarization (QRS complex)
- QRS complex: right and left ventricular depolarization (normally the ventricles are activated *simultaneously*)
- T wave: ventricular repolarization
- U wave: origin for this wave is not clear—but probably represents "after depolarizations" in the ventricles
- QRS duration: duration of ventricular muscle depolarization
- QT interval: duration of ventricular depolarization and repolarization
- RR interval: duration of ventricular cardiac cycle (an indicator of ventricular rate)
- PP interval: duration of atrial cycle (an indicator of atrial rate)

ONLINE

Post-Lab Online Exercise

Cardiac Conduction with Resultant EKG

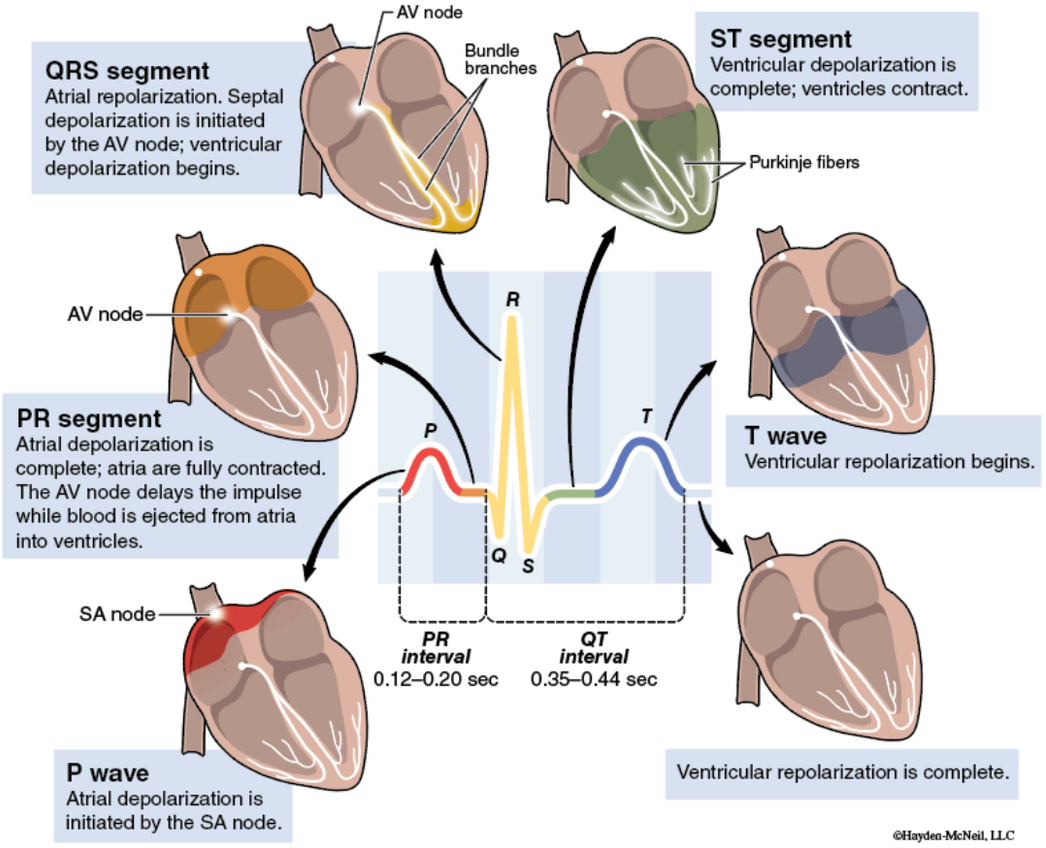

33

HEART ANATOMY

EKG Lead Placement

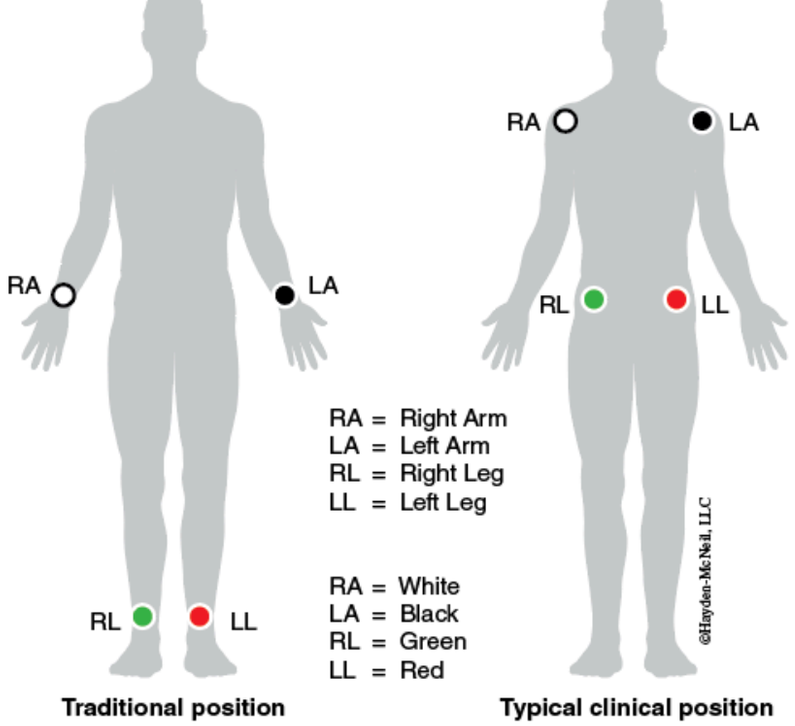

The limb leads are composed of *standard leads* I, II, and III and *augmented leads* aVL, aVR, and aVF.

Closer to chest/on chest reduces EKG signal interference.

Place the electrodes as follows:

- LA: left arm—either on the shoulder or the forearm
- RA: right arm—as above
- LL: left leg—either just below the knee or on the hip
- RL: right leg—as above

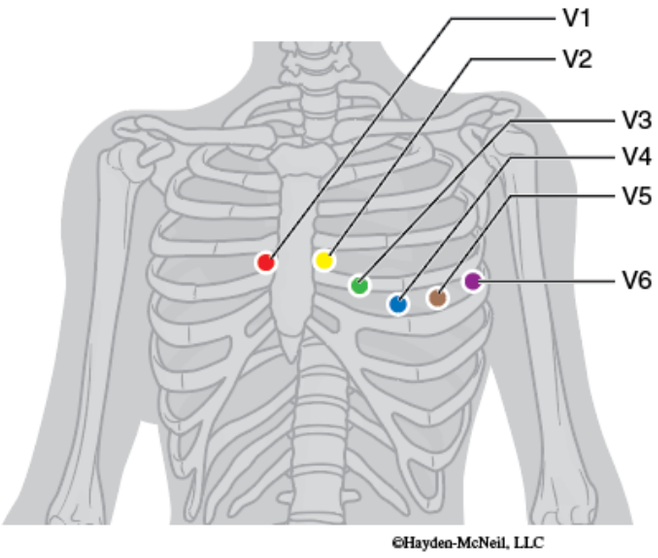

The precordial leads are placed on the chest, just above the heart. Their positions are as follows:

- **V1**: fourth intercostal space, at right edge of sternum (red)
- **V2**: fourth intercostal space, at left edge of sternum (yellow)
- **V3**: midway between V2 and V4 (green)

- **V4**: fifth intercostal space, midclavicular line (blue)
- **V5**: same horizontal line as V4, left anterior axillary line (brown)
- **V6**: same horizontal line as V4, left mid axillary line (purple)

ONLINE

I (Lateral)	aVR	V1 (Septal)	V4 (Anterior)	Specific leads give a specific view of the electrical activity of the heart. The chart at the left shows all the common EKG leads and what anatomical portion of the heart is being viewed. This is critical to know things such as seeing an injury pattern in leads V3 and V4, which could indicate a heart attack caused by blockage of the left anterior descending artery (LAD).
II (Inferior)	aVL (Lateral)	V2 (Septal)	V5 (Lateral)	
III (Inferior)	aVF (Inferior)	V3 (Anterior)	V6 (Lateral)	

Heart Physiology (Wiggers Diagram)

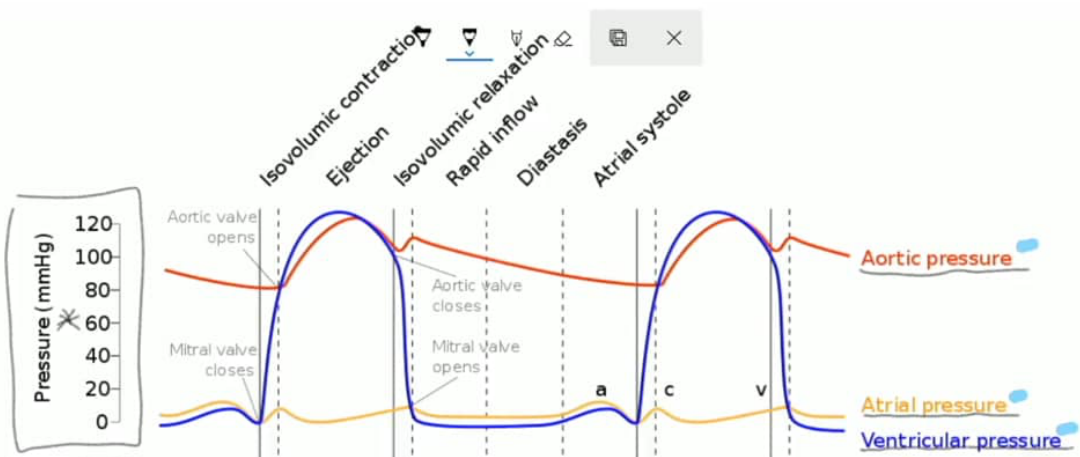

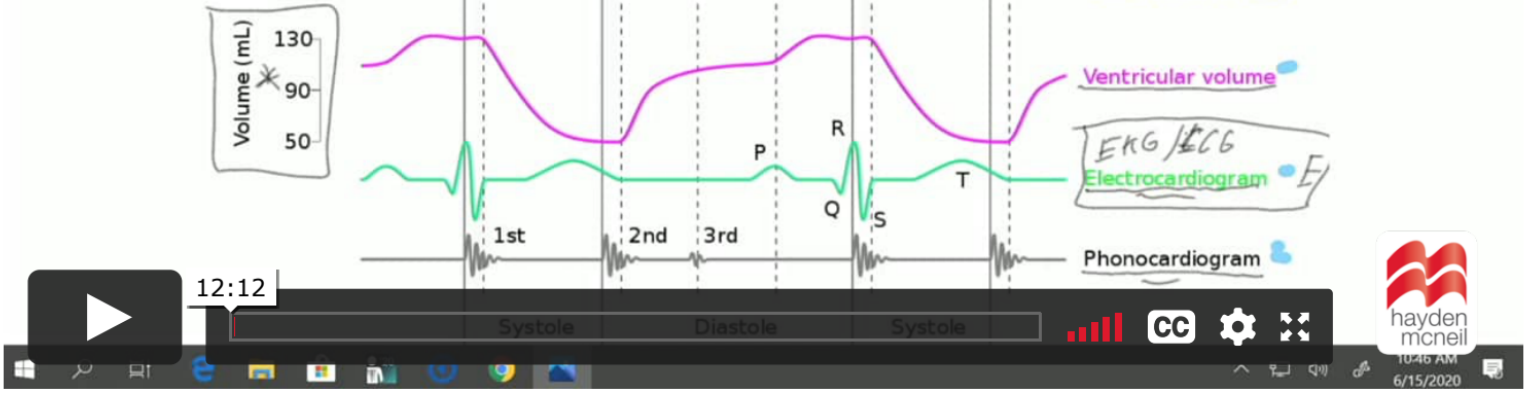

LEARNING GOAL

Learn how each event in the heart is connected

Wiggers Diagram is unique in the world of physiology as it shows what is occurring in at least 6 different variables associated with the heart at the exact same time!

As you can see from this fully labeled diagram there are 6 variables being measured at the same time: Phonocardiogram, Electrocardiogram, Ventricular Volume, Ventricular Pressure, Atrial Pressure and Aortic Pressure.

The 3 variables measuring pressure are labeled with the units mmHg, just as we measure with a blood pressure cuff; this is the standard unit of measure for cardiac pressure.

Volume is either milliliters or Liters; here we are dealing with small volumes of blood, so we use milliliters (mL).

Electrocardiogram (EKG or ECG) is electrical activity through the heart; it is not labeled here but it is usually measured in millivolts (mv).

Phonocardiogram (heart sounds), sound is typically measured in decibels (dB); they are not labeled here.



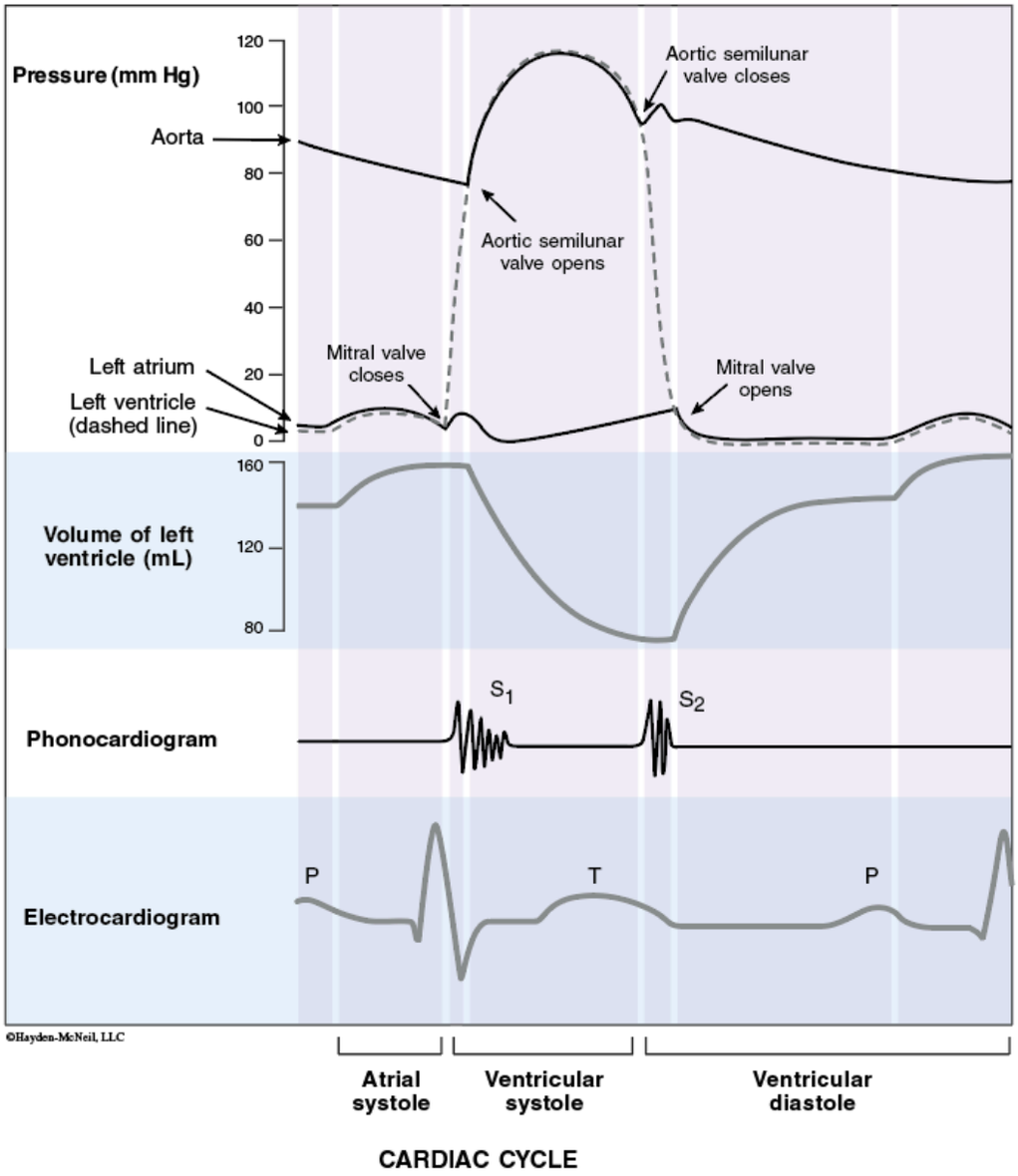

So what we need to do is figure out how all 6 of these variables are related or as I frequently put it in lecture "what causes what"!

I am sure there are many ways to go about analyzing this, but in my mind starting with the EKG makes the most sense, but before the EKG makes its first wave blood is flowing into the ventricles.

CONCEPTS TO HELP UNDERSTAND AND LEARN WIGGERS DIAGRAM

EKG causes all other changes.

- P wave is electrical indication of atrial depolarization.
  - Atrial depolarization results in atrial contraction.
  - Atrial contraction squeezes last 20 to 30% of blood out of atria into the ventricle.
  - Atrial contraction causes increased pressure in atria. This increased pressure in the atria is transmitted into the ventricle, along with the volume (look at volume and pressure curve for these variables).
- QRS is electrical indication of ventricular depolarization.
  - Ventricles begin contracting; AV valves close (first heart sound).
    - Ventricles continue contracting with AV valves closed and semilunar valves closed. No change in blood volume during this contraction (isovolumetric contraction). This causes pressure in the ventricle to increase very rapidly.
    - During isovolumetric contraction, blood in the aorta is at its lowest pressure. By definition, this is diastolic pressure. When the pressure in the ventricle exceeds the pressure on the other side of the semilunar valves, the valves are forced open. This is the start of ventricular ejection.
    - Once blood has left the ventricle and the heart relaxes, some blood backflows toward the heart. When this blood hits the semilunar valves, they close (second heart sound).
    - The backflowing blood in the aorta is also when the coronary arteries receive their blood flow. They do not get blood flow during ventricular ejection due to the openings being covered by the semilunar valves.
- Ventricular relaxation.
    - The cardiac muscle undergoes repolarization to become ready for the next depolarization and contraction.
    - While the heart is empty, this creates a vacuum, which in turn helps pull blood into the ventricles. Chest expansion during inhalation also creates a vacuum, helping blood return to the heart.
    - 70 to 80% of the returning blood to the heart enters the ventricles by passive flow from systemic and pulmonary circulation, through the atria, through the AV valves, and into the ventricles.

ONLINE

Pulse, Blood Pressure, and EKG Lab Questions

These questions should be completed during the lecture section of lab. Some questions have been asked in specific sections. Make sure you understand the answers; you will be tested on this information.

1. What is a pulse?
2. At which specific locations can you detect a pulse?
3. How are pulse and BP related?
4. What is systolic pressure?
5. What is diastolic pressure?
6. What is a pulse pressure?
7. What is mean arterial pressure?
8. Does it matter what position the extremity is in when taking a BP and why?
9. How could you determine systolic pressure without a BP cuff?
10. What does an EKG show or demonstrate?
11. What vital sign can you not tell from an EKG that you are making an assumption about?
12. What do the following waves on an EKG represent?
    - P
    - Q
    - R
    - S
    - T
13. What do the following intervals or segments on an EKG represent?
    - PR interval
    - QRS interval
    - ST segment
    - QT interval
14. Why are some EKG complexes upright (above the baseline) and others inverted (below the baseline)?
15. What does an EKG tell you about the person's blood pressure (can you tell a person's blood pressure from the EKG)?
16. What does exercise do to the following variables?
    - HR
    - Systolic
    - Diastolic
    - Pulse pressure

ONLINE

Post Lab Questions for Wiggers Diagram

Between heartbeats, ventricular diastole, there is a vacuum created by the emptying of the heart (from previous beat), the chest expanding (from inhalation) and the pressure of the muscle pump. How much blood is flowing into the ventricle at rest (ventricular diastole)?

- 0 mL, volume in the ventricle does not change
- 130 mL
- 50 mL

PART B—EKG

The next event is the atria contracting. What indication do we have for this on the EKG?

- QRS waves
- T wave
- P wave

PART C—ATRIAL CONTRACTION

As the atria contract, what happens to the pressure inside of the atria?

- Pressure goes up
- Pressure goes down
- Pressure does not change

PART D—VENTRICULAR PRESSURE AND VOLUME

So the atria have contracted; the last bit of blood that could be ejected from the atria into the ventricle has been ejected. When this last bit of blood (atrial kick) is ejected, two things occur in the ventricle: the volume of blood changes and the pressure changes. From the graph, answer the following question about what the volume and pressure are doing.

- Pressure goes up and volume goes up
- Pressure goes up and volume goes down
- Pressure and volume do not change

PART E—VENTRICULAR ACTIVITY

Now the electrical impulse has made its way through the conduction system into the ventricles and they are going to contract. What electrical event from the EKG tells us this is occurring?

- P wave
- QRS waves
- T wave

PART F—VALVES AND PRESSURE

So all the blood we are dealing with is now in the ventricles; the electrical signal has depolarized the ventricules and they are starting to contract. What does the pressure in the ventricle do and what valves are being shut from this pressure increase?

- Pressure in the ventricles goes up and there is no effect on the valves
- Pressure in the ventricles goes up and all the valves open
- Pressure in the ventricles goes almost straight up and the AV valves close.

PART G—SOUND

The two main sounds you hear listening (auscultating) to the heart are S1 and S2; both sounds are associated with the valves closing. Think about a door; does it make more noise when you slam it shut or open? The first heart sound (S1) occurs at the start of ventricular contraction (ventricular systole); which valves are being slammed shut?

- Aortic Semilunar
- Pulmonary Semilunar
- AV valves

PART H—ISOVOLUMETRIC CONTRACTION

As the ventricles contract, the valves are all closed, but the ventricle is contracting on the volume of blood! The pressure is going straight up; there is no change in volume, but the heart is contracting—thus, iso (same) volumetric (volume) contraction! At some point valves have to open. When and why does this occur? Think about a door that swings in both directions. There are people on one side pushing and you on the other side pushing; at what point can you push the door towards them? So what is the pressure we are pushing against? Blood leaves the ventricles through the semilunar valves. What is holding the valves shut? The pressure in the pulmonary system for the pulmonary semilunar valve, and pressure in the aorta for the aortic semilunar valve!

What pressure does the left ventricle have to overcome to open the aortic semilunar valve?

- Pulmonary pressure
- Aortic Pressure
- Superior Vena Cava

PART I—CARDIAC EJECTION

Once the semilunar valves have opened, blood can freely flow out of the ventricles into the pulmonary system (right ventricle) and to systemic circulation (left ventricle). Once the blood has been ejected there is some blood left above the valve (in the pulmonary system and in the aorta); this blood flows backwards at the start of diastole. This backflowing blood casue two valves to shut. Which valves?

- Bicuspid
- Pulmonary and Aortic Semilunar valves
- Tricuspid

PART J—HEART SOUNDS AGAIN

So this backflowing blood which closes valves is associated with what heart sound?

- S2—tricuspid valve closing
- S1—the mitral valve closing
- S2—pulmonary and aortic semilunar valves closing